

# Can we predict complications after elective carotid artery angioplasty and stenting with a simple Valsalva test?

BY VIKTOR ŠVIGELJ, MATJAZ ŠINKOVEC, VIKTOR AVBELJ, ROMAN TROBEC

## Abstract

**Objectives.** Arterial baroreflex plays a key role in short-term blood pressure balancing. It can also be quantified noninvasively with baroreceptor sensitivity during Valsalva manoeuvre. The aim of the study was to evaluate the role of Valsalva manoeuvre as a potential marker of possible autonomic dysfunction in patients after carotid artery angioplasty and stenting.

**Materials and methods.** We evaluated dynamic changes of blood pressure during Valsalva manoeuvre (Valsalva ratio, adrenergic baroreceptor sensitivity) in 22 patients (11 male;  $63.2 \pm 6.7$  years) with symptomatic, unilateral internal carotid artery stenosis, and compared results with age and sex matched control subjects.

**Results.** Valsalva ratio between baseline and post-procedural day ( $1.26 \pm 0.13$  vs  $1.46 \pm 0.31$ ;  $p=0.002$ ) was the only statistically significant parameter. All other tests (also between the study and the control group), cardiovagal and adrenergic, revealed no significant differences.

**Conclusion.** We were not able to show that Valsalva manoeuvre, as a simple, non-invasive and easy to perform test, could reliably confirm patients who are at a risk for postprocedural complications. It seems that most of the compensatory mechanisms, occurring after a revascularisation procedure, remain largely unclarified.

**Key words:** carotid stenosis, angioplasty, Valsalva manoeuvre, baroreceptor sensitivity, Valsalva ratio

## Introduction

Atherosclerosis, with carotid artery narrowing, is an important cause of ischaemic stroke. For patients with symptomatic carotid artery stenosis, percutaneous carotid angioplasty supported with stent (CAS) has emerged as a less invasive alternative to the gold standard surgical carotid endarterectomy (CEA). (1,2) The risk of composite primary outcome of stroke, myocardial infarction (MI) or death,

is similar between the procedures. There is, however, a higher risk of stroke with CAS and a higher risk of MI with CEA. (1,3) The majority of complications, such as cerebral embolism or hypoperfusion, and arterial dissection, occur during the procedure. (3) A potentially devastating complication, such as cerebral hyperperfusion syndrome (CHS), (4) can occur any time within the first month after the procedure, (5) mostly within several hours to several days. (6) It is reported to be a rare complication in the case of CEA (1%), (7) but not in the case of CAS (0.44 – 11.7 %). (5-7) Its precise pathophysiological mechanism is not yet clear and may be multifactorial. In addition to a high risk patient cohort (advanced age, high grade or bilateral stenosis, impaired collateral flow, etc.), (8) impaired cerebral autoregulatory function, and autonomic dysfunction may play a role. (9)

Therefore, our aim was to evaluate autonomic function in patients with high grade internal carotid artery stenosis before and after CAS and in a control group. A simple and safe autonomic function test – Valsalva manoeuvre (VM) – was used for this purpose.

## Materials and methods

This study was approved by the Republic of Slovenia National Medical Ethics Committee (No. 184/02/09). The study was conducted at the Division of Neurology, Department of Vascular Neurology and Neurological Intensive Care, University Medical Centre Ljubljana, Slovenia. A total of 22 patients (11 men, 11 women) and 22 age and sex matched healthy volunteers were included in the study after signed informed consent was obtained. All patients had unilateral symptomatic internal carotid artery (ICA) stenosis (70 – 99%) according to Doppler sonography criteria, confirmed with either digital subtraction angiography or computer tomography angiography, using criteria proposed in the literature. (10) According to the protocol, they were taking clopidogrel 75 mg and acetylsalicylic acid 100 mg 5 days before the CAS and 3 months after the procedure.

All recordings were made in the morning before the CAS procedure and the following morning. Results were compared to the single recordings obtained from the control group. Intra-procedural charts were evaluated for any intervention that could interfere with the reliability of the test, namely, the need for prolonged, high dose vasoactive drugs, sedatives or strong analgesics. In addition, a detailed neurological examination was performed after the procedure.

Heart rate was recorded using a standard 3-lead electrocardiogram. Computer-based analysis and calculation of time domain heart rate (HR) responses to VM were done (Nevro-EKG®, Intekomd.o.o.). Arterial blood pressure (ABP) was continuously measured at the finger using beat-to-beat photoplethysmographic recordings (Finapres, Ohmeda, model 2300). Valsalva manoeuvre was performed twice according to a proposed standard protocol and the most representative recording was evaluated. (11,12) For cardiovagal function testing, we calculated Valsalva ratio (VR) as the maximum HR generated by the VM in phase 2 divided by the lowest HR occurring within 30 seconds after the maximum HR. (13) For adrenergic function testing, baroreceptor sensitivity (BRS<sub>a</sub>) was calculated from ABP responses to VM. (14) BRS<sub>a</sub> test was defined as the systolic blood pressure

(SBP) decrement associated with phase 3 divided by the pressure recovery time (PRT). The PRT was defined as the interval between the lowest SBP of phase 3 and its return to baseline following the VM. (15)

Data were analysed using the Wilcoxon signed-rank test – a paired difference non-parametric test – to compare repeated measurements as well as matched control group measurements. Significance was set for a p value < 0.05. IBM SPSS Statistics, ver. 22 was used for statistical analysis.

## Results

Table 1.

All patients were treated with CAS according to the hospital standard protocol and were admitted on the day of the procedure. The patients' data are summarized in table 1. Most patients (95.5 %) had high grade carotid artery stenosis ( $\geq 80$  %). In almost 32 % of patients (either complaining of tinnitus or dizziness or both), stenosis was found accidentally during routine carotid artery auscultation, others suffered from minor stroke or transient ischemic attack (TIA).

Figure 1.

Two patients received 1 mg of atropine and 500 ml of 6 % hydroxyethyl starch (Volulyte) due to transient bradycardia and severe hypotension during the procedure. One patient needed a short-term infusion of dobutamine (2.5  $\mu\text{g}/\text{kg}/\text{min}$ ) due to sustained bradycardia and hypotension. In one 75-year old patient, a transient CHS was suspected on the morning after the right-sided ICA CAS. He complained of severe headache and dizziness. The computed tomography (CT) scan did not reveal any new pathology except for an old infarction (figure 1A). The patient was discharged from hospital two days later without any symptoms. To illustrate the CHS after CAS, we present a 65-year old patient who was not included in this study since he refused the testing (figure 1B). No complaints were demonstrated one month after the procedure when both patients had a routine carotid Doppler sonography.

Table 2.

The results of VM testing are shown in table 2. Cardiovagal function in patients, tested with VR at baseline and on post-procedural day, changed significantly ( $p = 0.002$ ). No statistically significant differences were found between patients and controls.

Figure 2.

Blood pressure responses to VM are shown in figure 2. No significant changes of adrenergic function, tested with BRS\_a, were demonstrated in patients and between patients and controls.

## Discussion

Modern and noninvasive autonomic function tests are sensitive methods for evaluating cardiovagal, sudomotor and adrenergic autonomic functions and can detect also subclinical dysautonomias. (13) The idea of our study was whether we can use, in routine clinical practice, some of the methods for assessment of the autonomic nervous system, particularly those that are simple, short and reliable for diagnosing patients at risk for deleterious complications, such as CHS after CAS procedure. It seems that with the Valsalva manoeuvre, cardiovagal, as well as adrenergic autonomic functions, could be reliably tested. (13,15,16)

In patients, we demonstrated a statistically significant change in cardiovagal function (tested with VR) between baseline and post-procedural day. This transient post-operative parasympathetic hyperactivity explains the lower SBP, which has been observed in most patients after CAS. It is possible however, that intact cerebral autoregulation prevented complications, such as CHS. Patients, treated with CAS, were fasting before, and sometimes even after the procedure and they were frequently dehydrated. This may again be in favour of cerebral vascular autoregulation after CAS as a possible mechanism that prevented more CHS cases (figure 1), despite the fairly low BP demonstrated in most patients after CAS. Similar results are found in other studies showing the time dependant adaptation of BR. This may be the consequence of underlying disease, rather than from the procedure itself. (17,18) It is also possible that extra-carotid BR areas have a large ability to compensate for the loss of carotid BR. (19,20)

Adrenergic function, measured as BRS<sub>a</sub>, did not reveal any differences before and after the procedure in our cohort of CAS patients as well as when the results were compared with the control group. Some reasons might be: older age of our patients, history of hypertension in the majority, and treatment with one or more antihypertensive drugs.

The limitations of our study are: low number of the study population, as well as the lack of comparison of the VM test to other autonomic test, such as deep breathing or tilt table test. In the future we have to implement our testing with some other mathematical models, e.g. respiratory BRS, which could be more sensitive for revealing subclinical dysautonomias.

## **Conclusion**

In our cohort of patients, we demonstrated a statistically significant change in cardiovagal function (tested with VR) between baseline and post-procedural day. This transient post-operative parasympathetic hyperactivity explains the lower SBP, which has been frequently observed in most patients after CAS.

We were not able to reliably identify patients who are at risk for post procedural CHS. It seems that most of the cardiovascular compensatory mechanisms, occurring after CAS, remain largely unclarified.

Table 1. Baseline characteristics in the cohort of patients treated with carotid angioplasty and stent, and in age and sex matched control group of healthy volunteers.

Variables	Patients(n = 22)	Control group(n = 22)	p
Age (Mean ± SD) years	63.2 ± 6.7	62.7 ± 6.9	ns
Previous stroke or TIA, no. (%)	15 (68,2)	NA	NA
Treated hypertension, no. (%)	19 (86,4)	none	NA
Left ICA stenosis, no. (%)	16 (80)	NA	NA
Grade of ICA stenosis no. (%)		NA	NA
70 – 79 %	1 (4,5)		
80 – 89 %	13 (59,1)		
> 90 %	8 (36,4)		

ICA, internal carotid artery; NA, not applicable; ns, not significant; p, significance at p value > 0.05; TIA, transitory ischaemic attack.

Table 2. Adrenergic and cardiovagal function tests obtained by the Valsalva manoeuvre in a cohort of treated patients with carotid angioplasty supported with stent and compared to a control group.

Parameters	Values (Mean ± SD)			
	VR	BRS_a (mmHg/s)		
		Before CAS	Day after CAS	Before CAS Day after CAS
Study group	1.26 ± 0.13	1.46 ± 0.31	4,86 ± 3,19	4.92 ± 3,76
p value	0.002	ns		
Control group	1.42 ± 0.31	6.99 ± 5.90		
p value	ns	ns	ns	ns

BRS\_a, baroreceptor sensitivity as a measure of adrenergic function; CAS, carotid angioplasty supported with stent; ns, not significant; p value, p value of Wilcoxon signed-rank test; SD, standard deviation; VR, Valsalva ratio.

Figure 1. A head computed tomography (CT) scan of the patient a day after the revascularisation procedure in the right internal carotid artery, suspected to have cerebral hyperperfusion syndrome (A), showing an old infarction, but no new lesions, and a head CT scan of a patient with clear CT signs of the cerebral hyperperfusion syndrome (B).

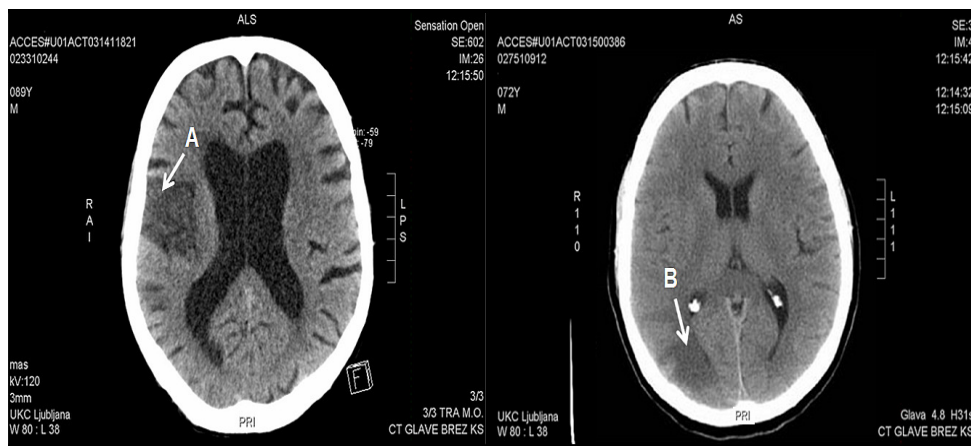
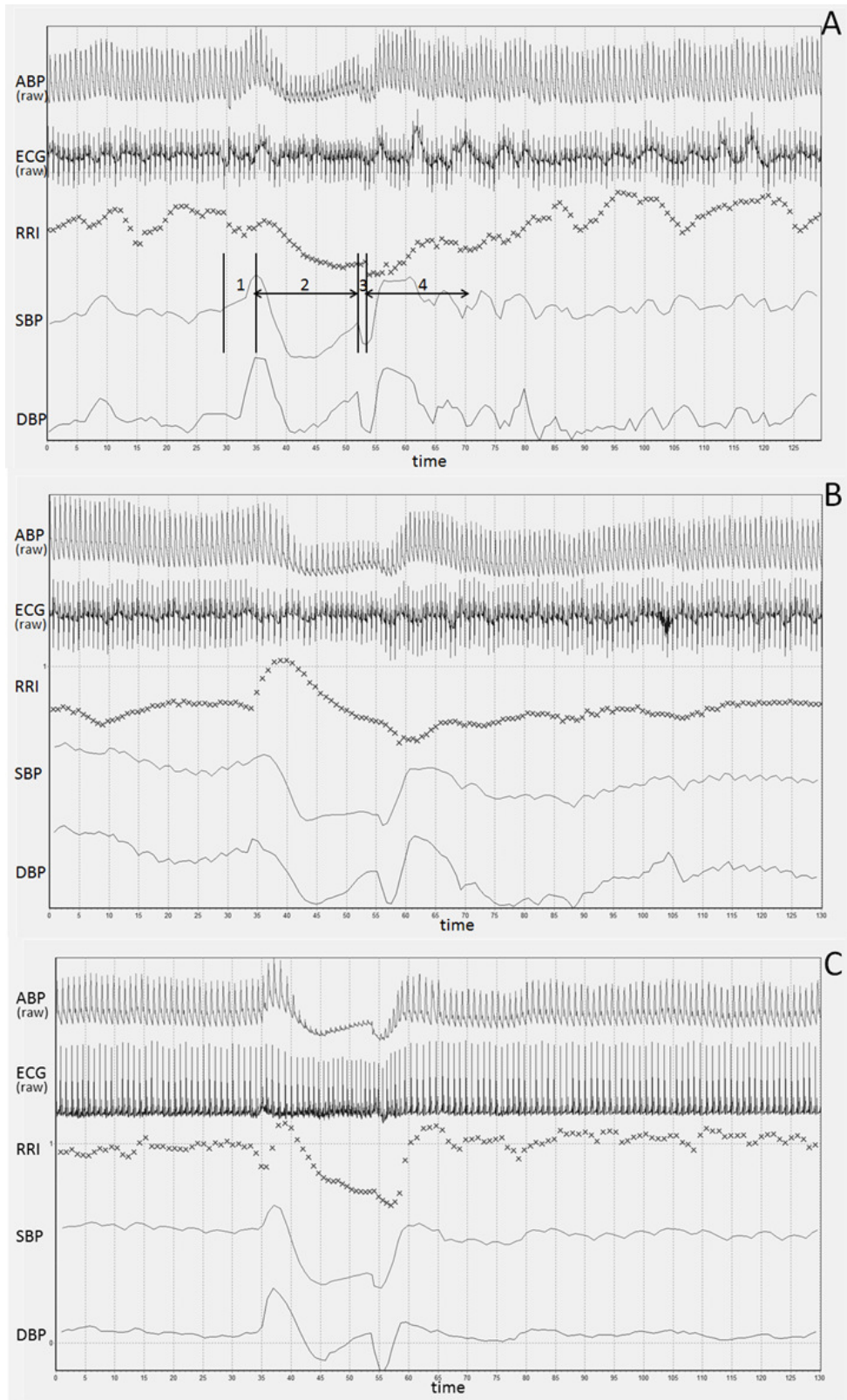


Figure 2. A 4-phase blood pressure profile evoked by Valsalva manoeuvre in a patient, suspected to have cerebral hyperperfusion syndrome before the revascularisation procedure (A) and a day after the procedure, compared to a recording from a healthy subject (C). There are no clear phase differences

between the recordings.



ABP (raw), raw signal of the arterial blood pressure recorded with Finapres, Ohmeda, model 2300 recorder; ECG (raw), raw electrocardiographic recording recorded with Nevro-EKG®, Intekomd.o.o.; DBP, processed signal of diastolic blood pressure; RRI, R to R wave interval; SBP, processed signal of systolic blood pressure; 1, Valsalva manoeuver phase I; 2, Valsalva manoeuver phase II; 3, Valsalva manoeuver phase III; 4, Valsalva manoeuver phase IV.

## References

1. Brott TG, Hobson RW, Howard G, Roubin GS, Clark WM, Brooks W, et al. Stenting versus Endarterectomy for Treatment of Carotid Artery Stenosis. *N Engl J Med* 2010;363(1):11-23.
2. Kozar S, Jeromel M. Hyperperfusion and Intracranial Haemorrhage After Carotid Angioplasty With Stenting – Latest Review. *Signa Vitae* 2014;9(2):9-14.
3. Narita S, Aikawa H, Nagata S, Tsutsumi M, Nii K, Yoshida H, et al. Intraprocedural Prediction of Hemorrhagic Cerebral Hyperperfusion Syndrome After Carotid Artery Stenting. *J Stroke Cerebrovasc Dis* 2013;22(5): 615-9.
4. Coutts SB, Hill MD, Hu WY. Hyperperfusion syndrome: toward a stricter definition. *Neurosurgery* 2003;53:1053-8.
5. Ogasawara K, Mikami C, Inoue T, Ogawa A. Delayed cerebral hyperperfusion syndrome caused by prolonged impairment of cerebrovascular autoregulation after carotid endarterectomy: case report. *Neurosurgery* 2004;54:1258-62.
6. van Mook WN, Rennenberg RJ, Schurink GW, van Oostenbrugge RJ, Mess WH, Hofman PA, et al. Cerebral hyperperfusion syndrome. *Lancet Neurol* 2005;4:877-88.
7. Bouri S, Thapar A, Shalhoub J, Jayasooriya G, Fernando A, Franklin IJ, et al. Hypertension and the post-carotid endarterectomy cerebral Hyperperfusion Syndrome. *Eur J Vasc Endovasc Surg* 2011;41:229-37.
8. Canovas D, Estela J, Perendreu J, Branera J, Rovira A, Martinez M, et al. Cerebral hyperperfusion syndrome after angioplasty. In: Forbes T, editor. *Angioplasty, various techniques and challenges in treatment of congenital and acquired vascular stenoses*. Shanghai: InTech; 2012. p. 9-40.
9. Goldberg JB, Goodney PP, Kumbhani SR, Roth RM, Powell RJ, Likosky DS. Brain Injury After Carotid Revascularisation: Outcomes, Mechanisms, and Opportunities for Improvement. *Ann Vasc Surg* 2011;25:270-86.
10. von Reutern GM, Goertler MW, Bornstein NM, Del Sette M, Evans DH, Hetzel A, et al. Recommendations for grading carotid stenosis by means of ultrasonic methods. *Stroke* 2012;43:916-21.
11. Benarroch EE, Opfer-Gehrking TL, Low PA. Use of the photoplethysmographic technique to analyze the Valsalva maneuver in normal man. *Muscle & Nerve* 1991;14:1165-72.
12. Denq J-C, O'Brien PC, Low PA. Normative data on phases of Valsalva maneuverer. *J Clin Neurophysiol* 1998;15:535-40.
13. Low PA, Tomalia VA, Park KJ. Autonomic function: some clinical applications. *J Clin Neurol* 2013;9:1-8.
14. Vogel ER, Sandroni P, Low PA. Blood pressure recovery from Valsalva maneuverer in patients with autonomic failure. *Neurology* 2005;65:1533-7.
15. Schrezenmaier C, Singer W, Muentert Swift N, Sletten D, Tanabe J, Low PA, Adrenergic and vagal baroreflex sensitivity in autonomic failure. *Arch Neurol* 2007;64:381-6.
16. Novak P. Assessment of sympathetic index from Valsalva maneuverer. *Neurology* 2011;76:2010-6.
17. Yakhou L, Constant I, Merle JC, Laude D, Becquemin JP, Duvaldestin P. Noninvasive investigation of autonomic activity after carotid stenting or carotid endarterectomy. *J Vasc Surg* 2006;44:472-9.
18. Huang C-C, Wu Y-S, Chen T, Chang W-N, Du Y-C, Wu C-J, et al. Long-term effects of baroreflex function after stenting in patients with carotid artery stenosis.

Auton Neurosci 2010;158:100-4.

19. Bishop VS, Haywood JR, Shade RE, Siegel M, Hamm C. Aortic baroreceptor deafferentation in the baboon. *J Appl Physiol* 1986;60:798-801.
20. Shade RE, Bishop VS, Haywood JR, Hamm CK. Cardiovascular and neuroendocrine responses to baroreceptor denervation in baboons. *Am J Physiol* 1990;258:R930-8.

Viktor Švigelj

Department of Vascular Neurology and Neurological Intensive Care, Neurological Intensive Care Unit, Division of Neurology, University Medical Centre Ljubljana, Ljubljana, Slovenia

Matjaž Šinkovec

Department of Cardiology, Division of Internal Medicine, University Medical Centre Ljubljana, Ljubljana, Slovenia

Viktor Avbelj, Roman Trobec

Department of Communication Systems, Jozef Stefan Institute, Ljubljana, Slovenia

Corresponding author:

Viktor Švigelj

Department of Vascular Neurology and Neurological Intensive Care

Neurological Intensive Care Unit

Division of Neurology

University Medical Centre Ljubljana

Zaloška 2, 1525 Ljubljana, Slovenia

Phone: +386 1 522 4846

Fax: +386 1 522 1332

E-mail: viktor.svigelj@kclj.si).

SIGNA VITAE 2015; 10(1): 93-102